

CASO CLÍNICO



.....

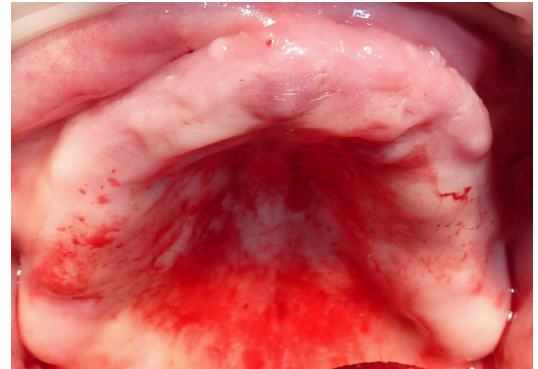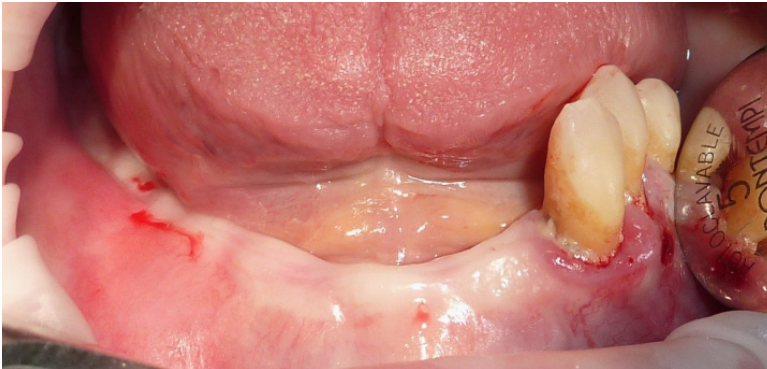
RESTAURACIÓN COMPLETA IMPLANTOSOPORTADA I

.....

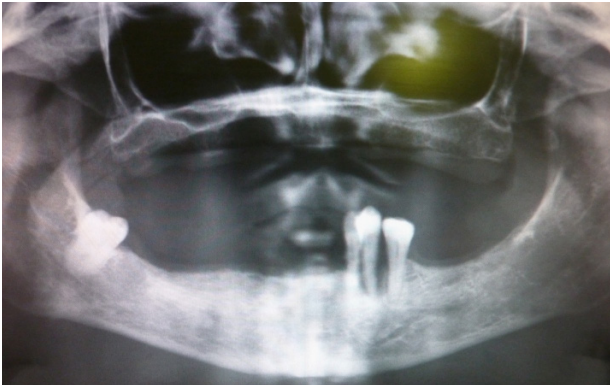
Dr. Leví Cuadrado

A decorative graphic in the bottom-left corner consisting of overlapping curved shapes in light teal and light blue.

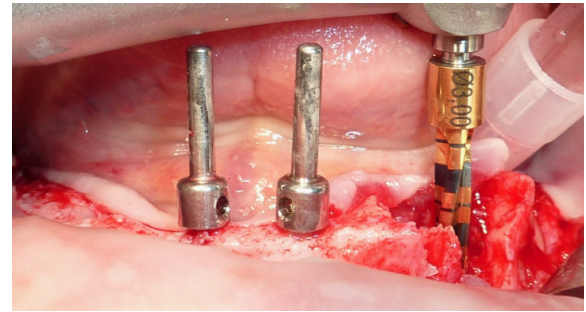
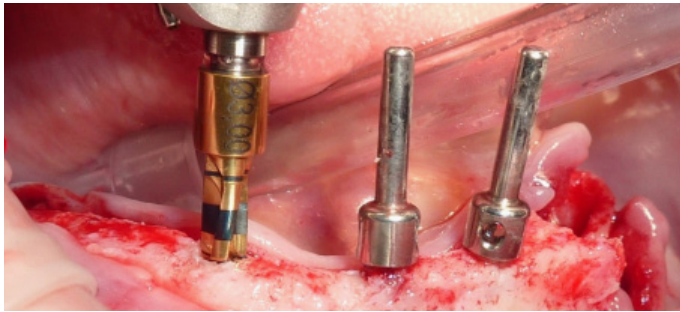
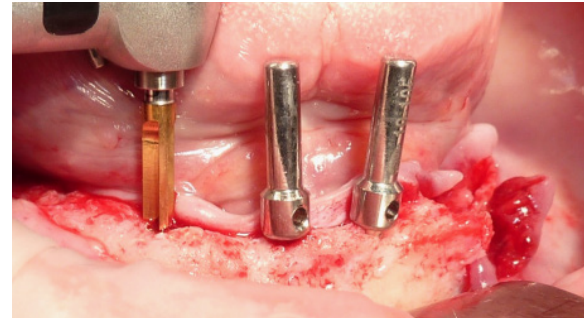
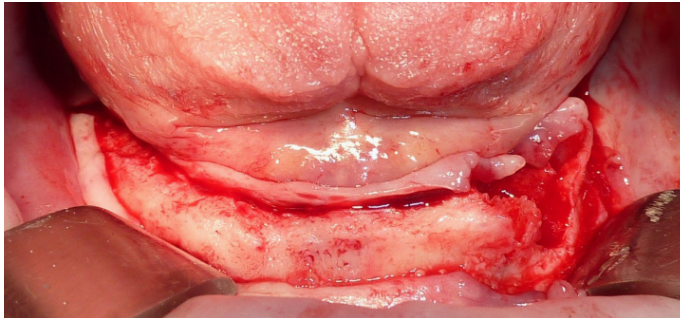
Fotografías Pre-operatorias

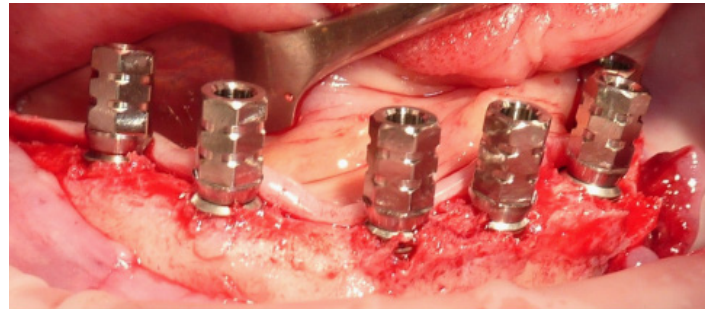
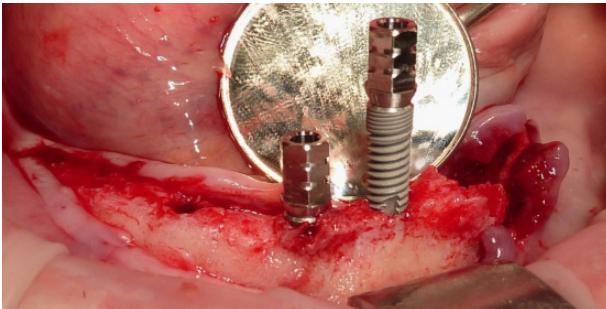
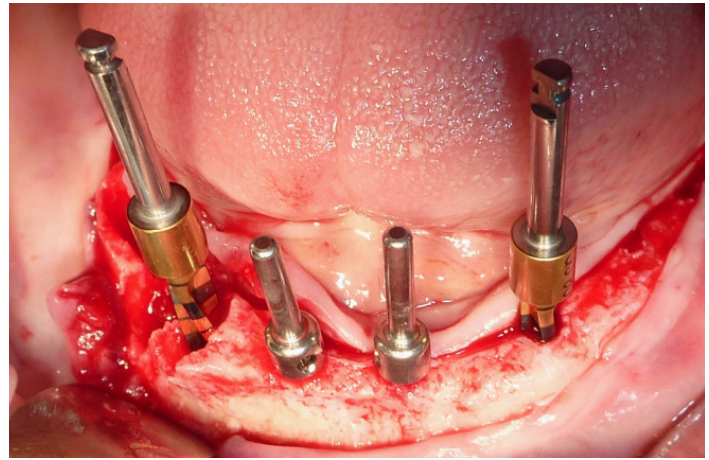
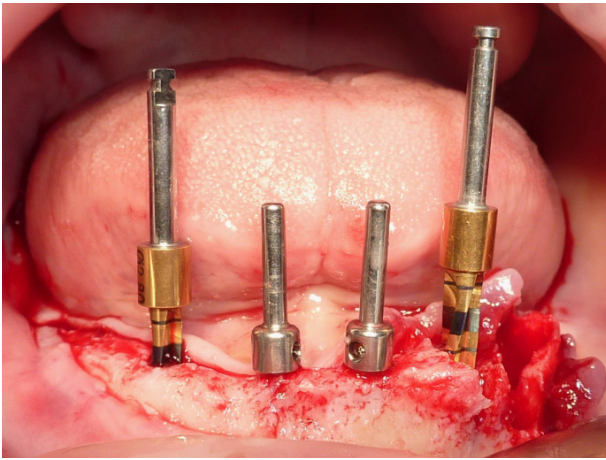


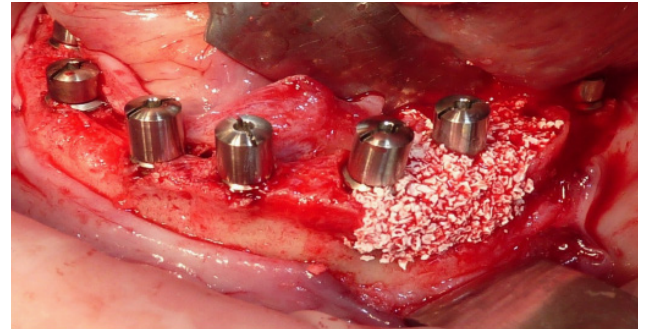
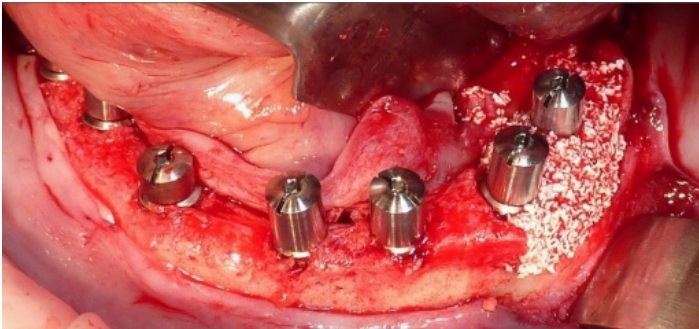
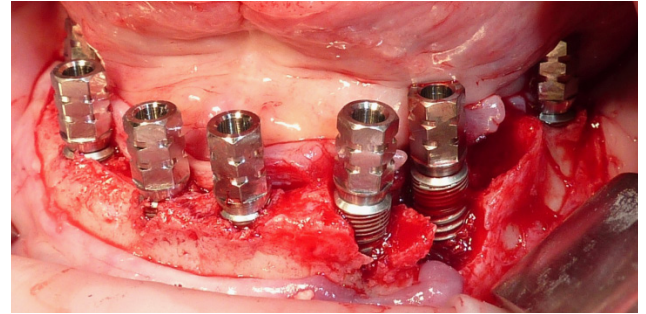
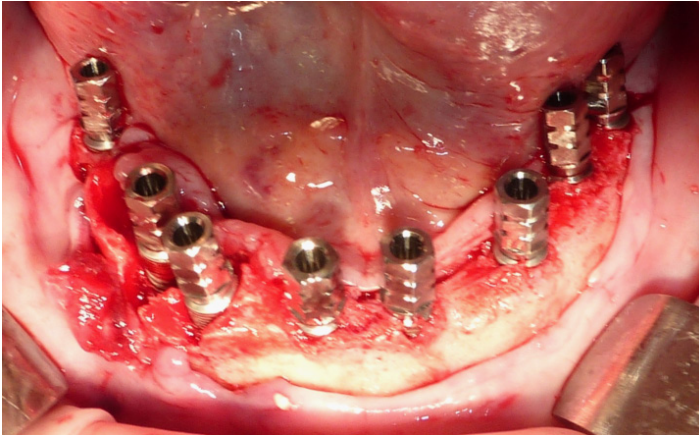
Control Radiográfico

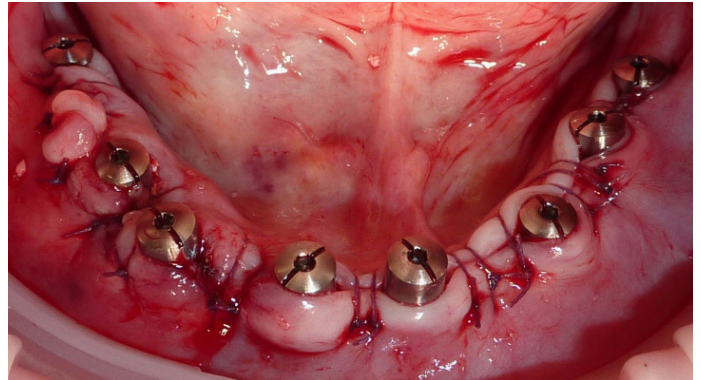
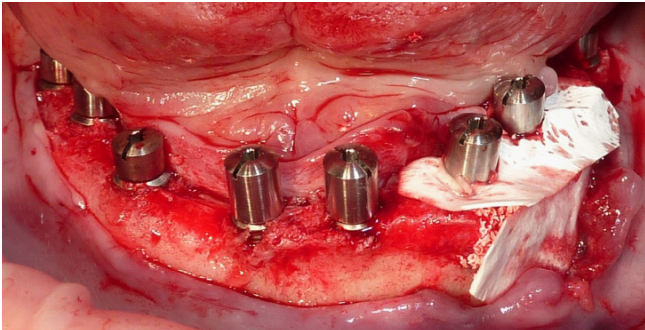
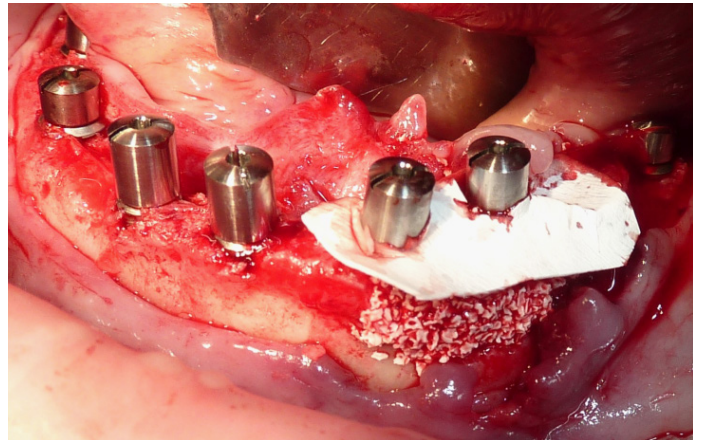
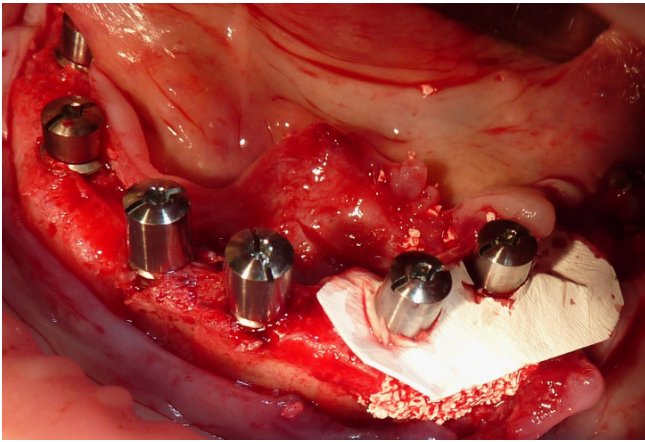


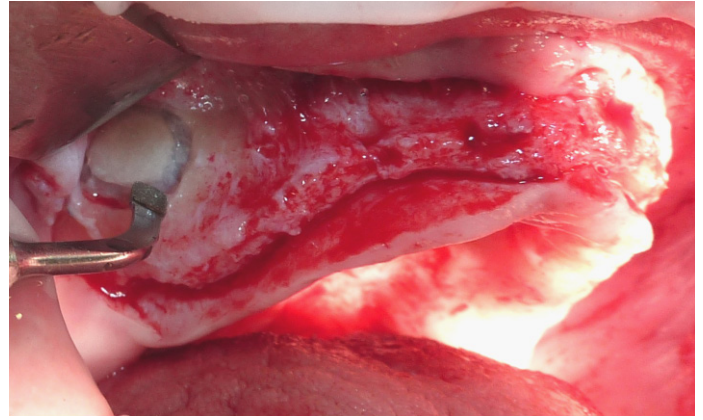
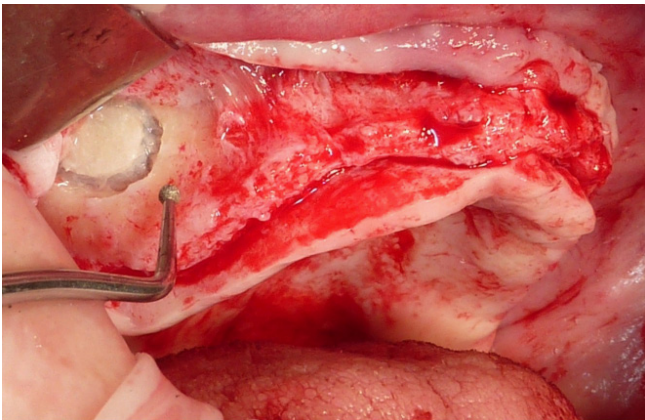
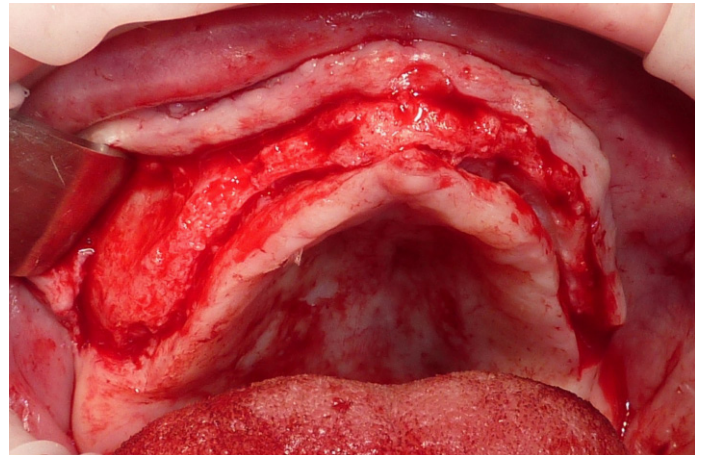
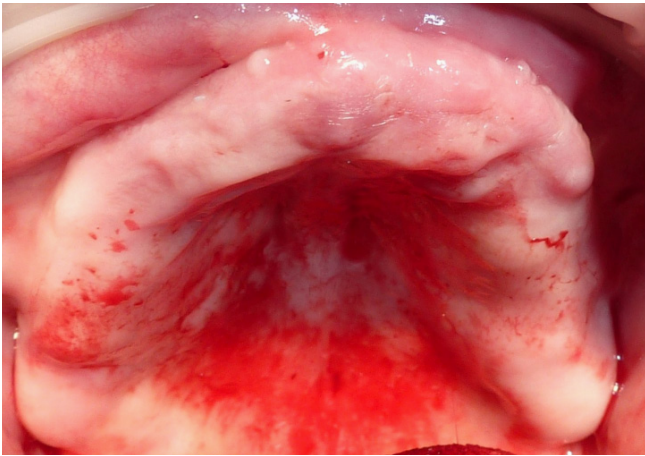
Intervención quirúrgica

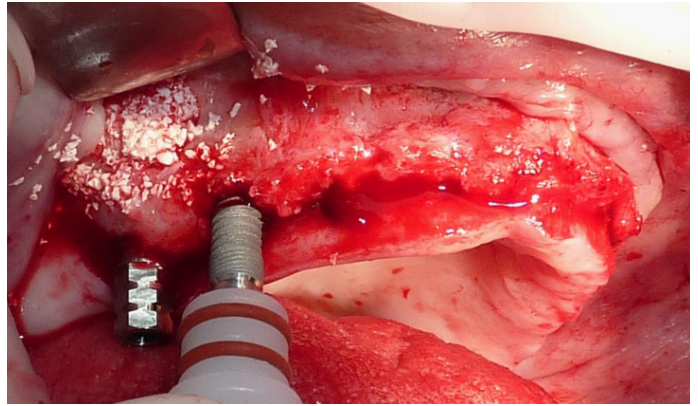
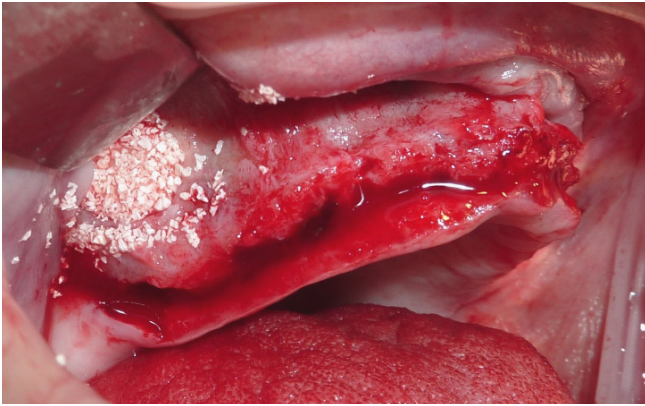
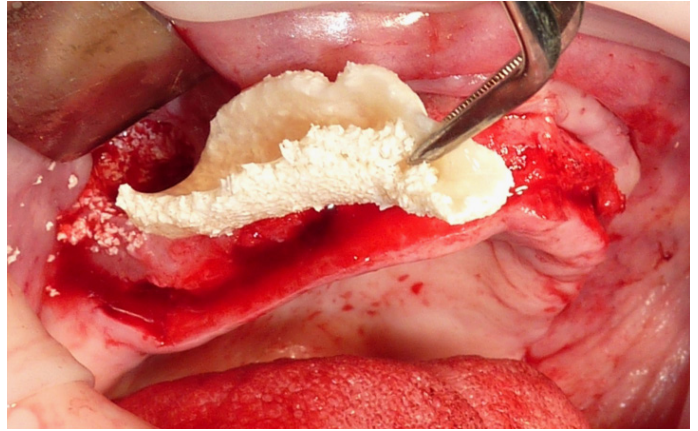
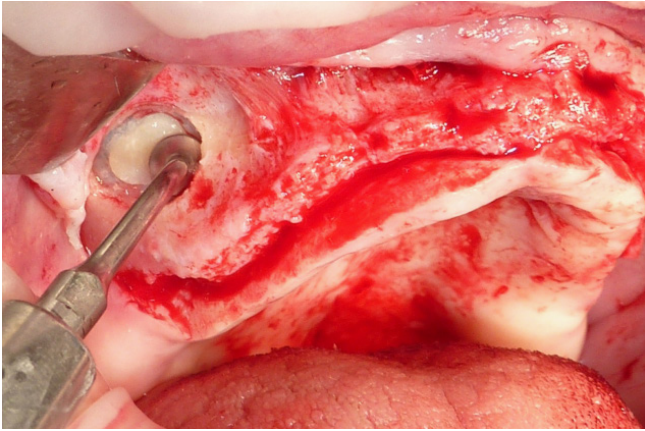


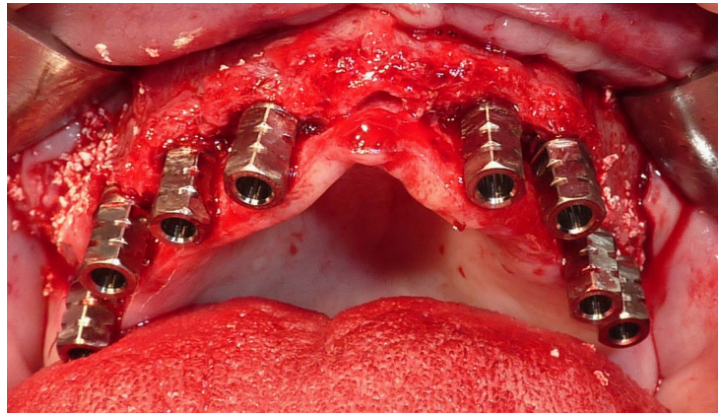
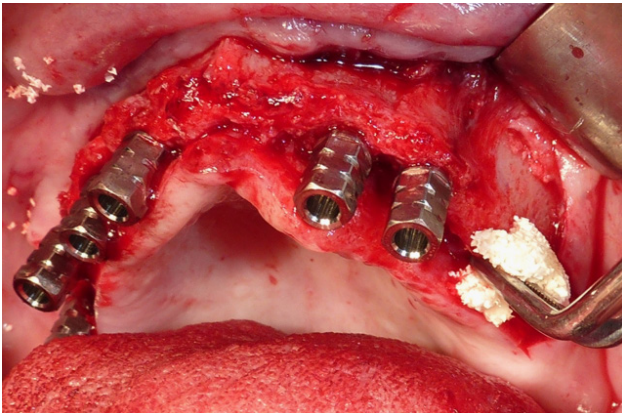
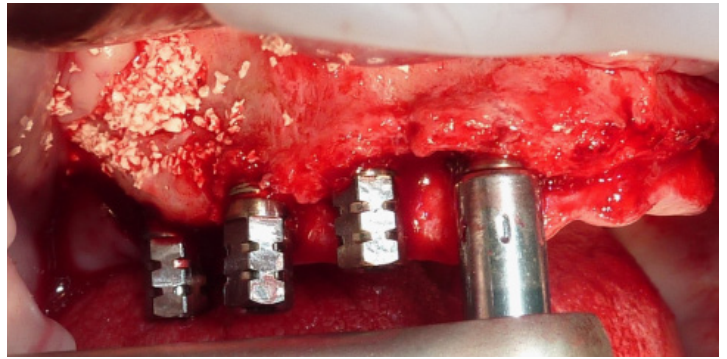
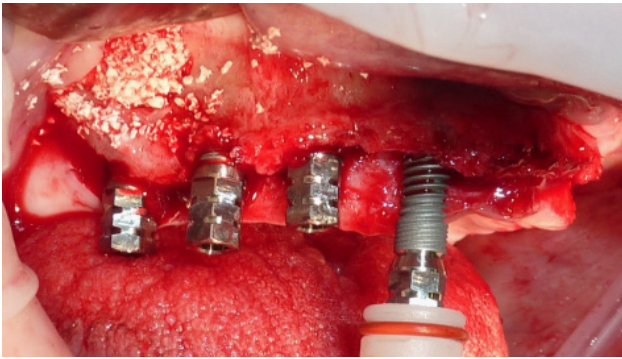


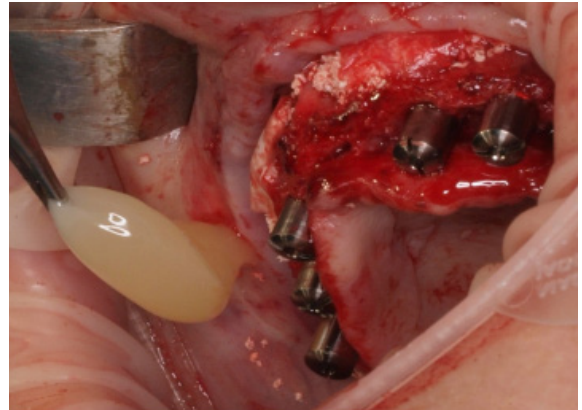
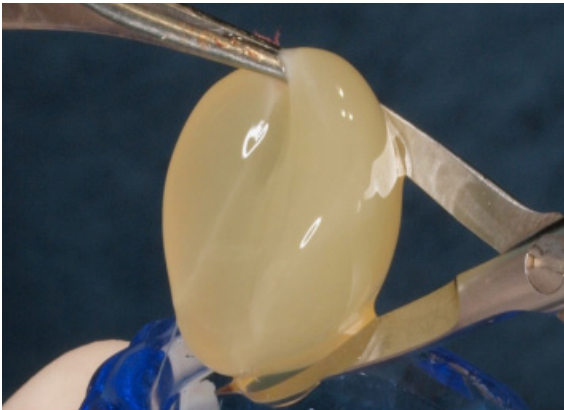
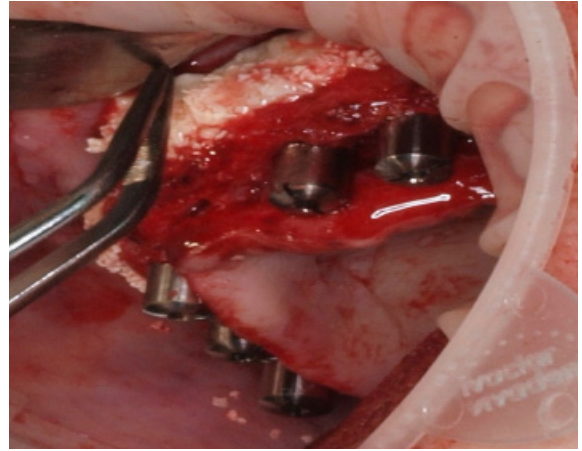
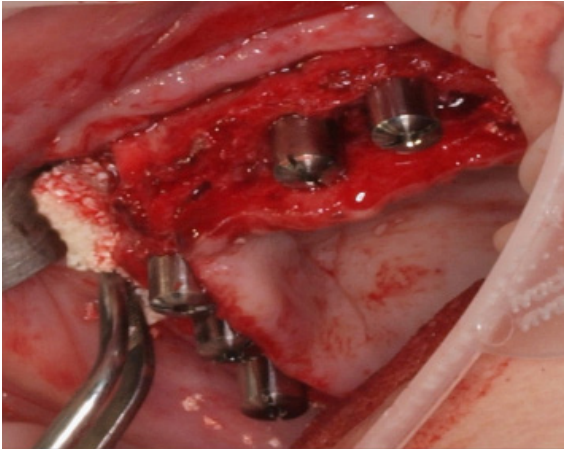


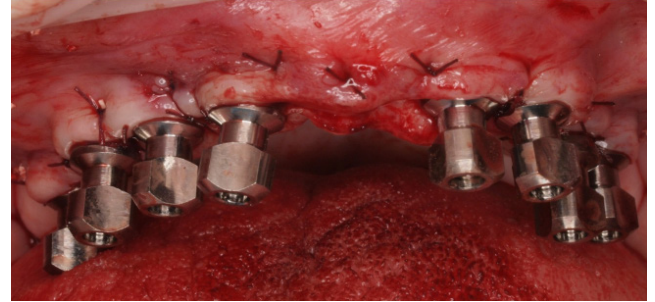
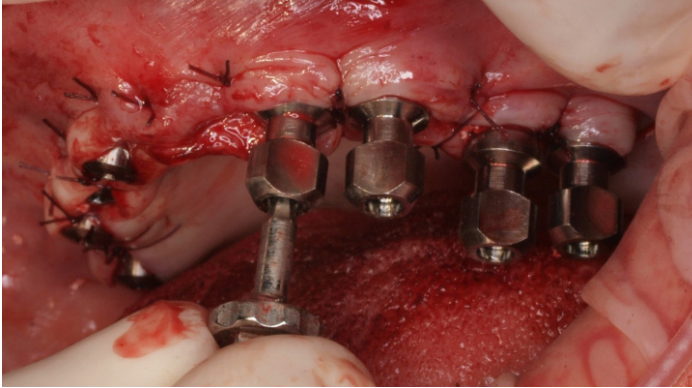
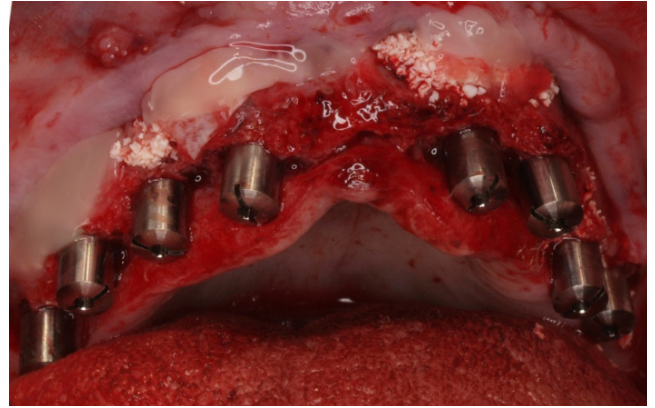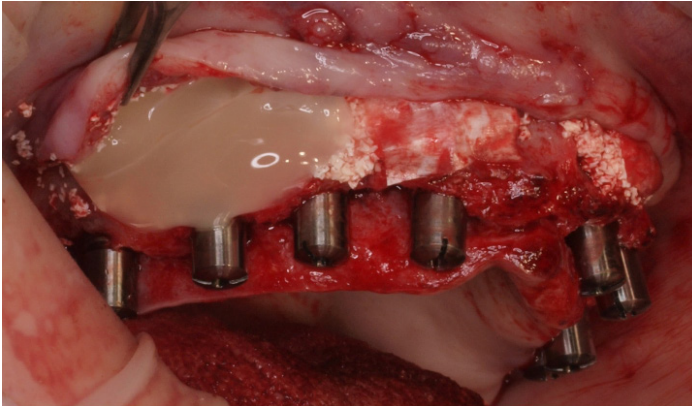


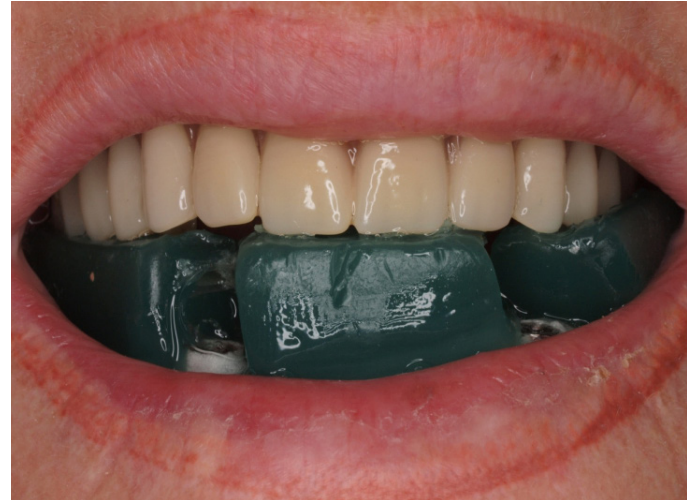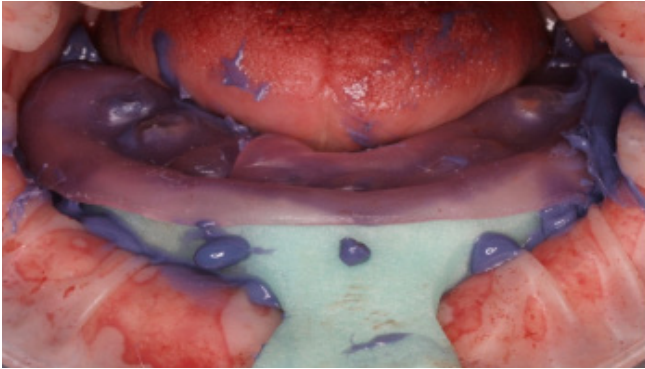
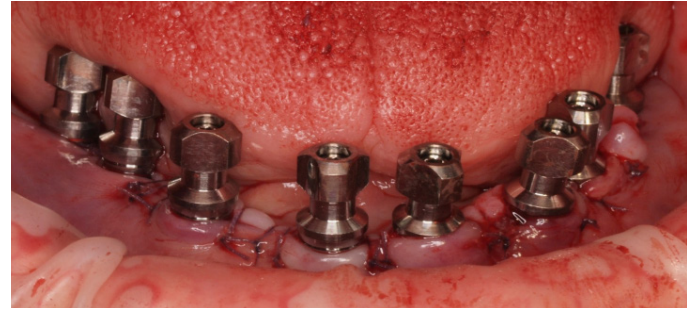


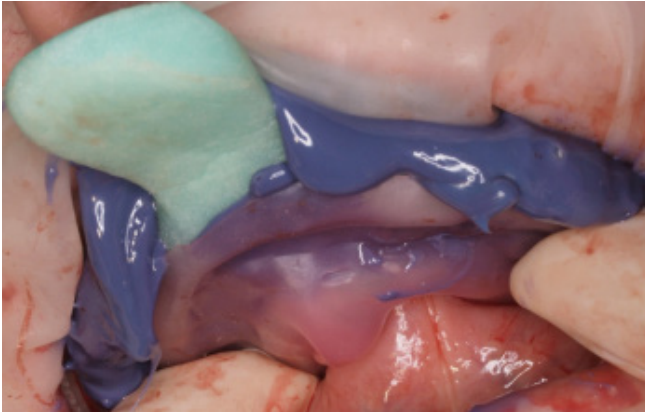

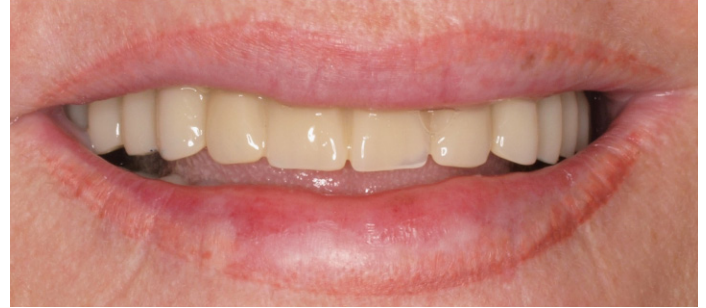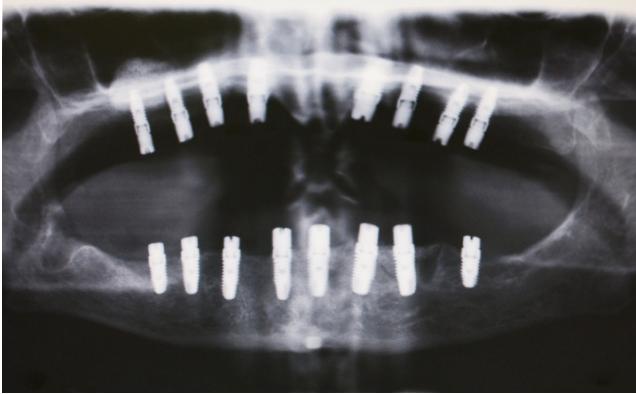








Control Radiográfico post-operatorio



Control a los 8 meses

